Result Screen shots:

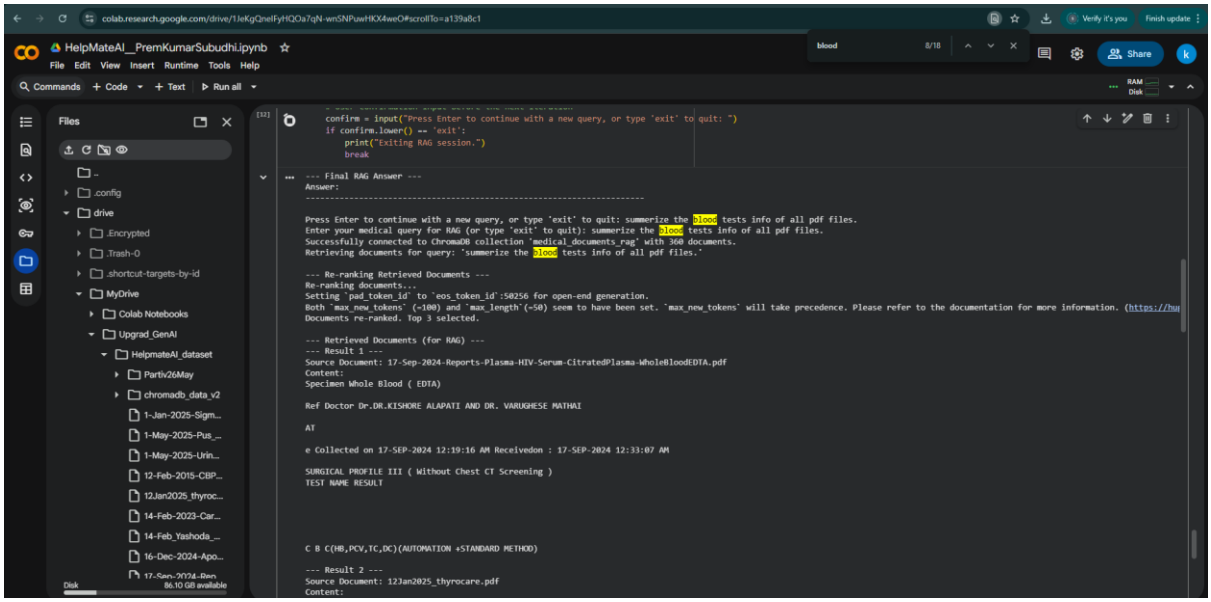

HelpMateAI__PremKumarSubudhi.ipynb

```
confirm = input("Press Enter to continue with a new query, or type 'exit' to quit: ")
if confirm.lower() == 'exit':
    print("Exiting RAG session.")
    break
```

```
"The test results were taken from the first test of a large body of blood. The blood volume was measured at an average of 1.6 ml/g. In all the blood, every 8 mm (4.5 in) of blood wa
--------------------------------------------------------------------------------

Press Enter to continue with a new query, or type 'exit' to quit: summerize the latest test ststus
Enter your medical query for RAG (or type 'exit' to quit): summerize the latest test status
Successfully connected to ChromaDB collection 'medical_documents_rag' with 360 documents.
Retrieving documents for query: 'summerize the latest test status'

--- Re-ranking Retrieved Documents ---
Re-ranking documents...
Setting `pad_token_id` to `eos_token_id`:50256 for open-end generation.
Both `max_new_tokens` (=100) and `max_length`(=50) seem to have been set. `max_new_tokens` will take precedence. Please refer to the documentation for more information. (https://hu
Documents re-ranked. Top 3 selected.

--- Retrieved Documents (for RAG) ---
--- Result 1 ---
Source Document: 12Jan2025_thyrocare.pdf
Content:
enesleernemnrnsnanrentiWtitNentARATERANUNE SANE NA TE AANA



F scceeicesnanmmetserntsensrnnctnaneiecstesmrnaeiamtnerann
Sample Collected on (SCT) 212 Jan 2025 07:09 .
Sample Received on (SRT) +13 Jan 2025 04:38 "


ih yer
Report Released on (RRT) :13 Jan 2025 10:21 Qype
a



PROCESSED AT:
```

HelpMateAI__PremKumarSubudhi.ipynb

```
confirm = input("Press Enter to continue with a new query, or type 'exit' to quit: ")
if confirm.lower() == 'exit':
    print("Exiting RAG session.")
    break
```

```
ACCREDITED

D-37/1,TTC MIDC,Turbhe, Grice shmeecnlanrooa 4 Thyroca re

Navi Mumbai-400 703


Tests you can trust

--- Result 3 ---
Source Document: 12Jan2025_thyrocare.pdf
Content:
Navi Mumbai-400 703


Tests you can trust

Corporate Office : Thyrocare Technologies Limited, @ D-37/1, TTC MIDC, Turbhe, Navi Mumbai - 400 703
@ 022 - 3090 0000 / 6712 3400 @ 9870666333 &% wellness@thyrocare.com @ www.thyrocare.com


NAME : KK V SUBUDHI(81Y/M) HOME COLLECTION :

REF. BY = DR. CARE PREM KUMAR SUBUDHI FLAT 207 EDEN A LODHA
. APPARTMENT NEAR SANATH NAGAR BUSSTAND

TEST ASKED : BLOOD SUGAR (F),FESTIVE HEALTHY COUPLE HYDERABAD TELANGANA PIN500018 9937273150


--- Generating Answer with LLM ---

--- Final RAG Answer ---
The test status has been confirmed
```

colab.research.google.com/drive/1JeKgQneIFyHQOa7qN-wn5NPuwHKX4weO#scrollTo=a139a8c1

HelpMateAI__PremKumarSubudhi.ipynb

```
The test status has been confirmed
--------------------------------------------------------------------------------

Press Enter to continue with a new query, or type 'exit' to quit: share the CBP paramertes of latest report
Enter your medical query for RAG (or type 'exit' to quit):  share the CBP paramertes of latest report
Successfully connected to ChromaDB collection 'medical_documents_rag' with 360 documents.
Retrieving documents for query: ' share the CBP paramertes of latest report'

--- Re-ranking Retrieved Documents ---
Re-ranking documents...
Setting `pad_token_id` to `eos_token_id`:50256 for open-end generation.
Both `max_new_tokens` (=100) and `max_length`(=50) seem to have been set. `max_new_tokens` will take precedence. Please refer to the documentation for more information. (https://hu
Documents re-ranked. Top 3 selected.

--- Retrieved Documents (for RAG) ---
--- Result 1 ---
Source Document: 12-Feb-2015-CBP-CUE-RFT-PUSCULTURE-CT-ABDOMEN.pdf
Content:
10.60

32.30

92.00

30.20

32.8

17.10

3.30

7.90

11,120.00

75.00


Billed on : 12/02/2025 02:43:41 AM
Collected on =: 12/02/2025 05:36:50 AM
Received on =: 12/02/2025 05:54:18 AM
Reportedon -: 12/02/2025 06:36:27 AM
```

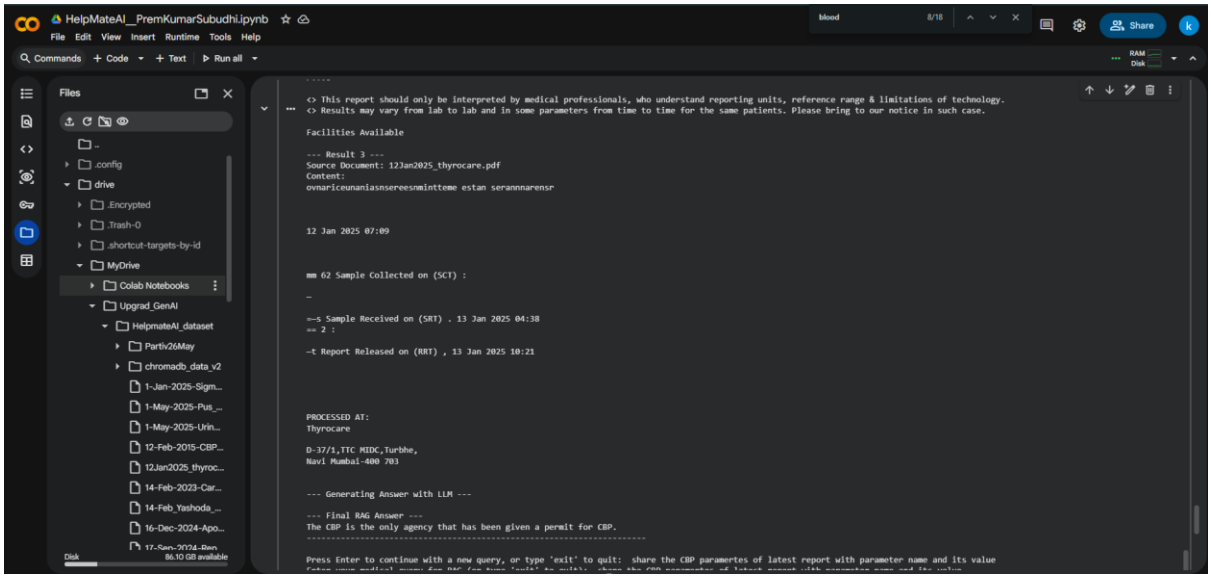

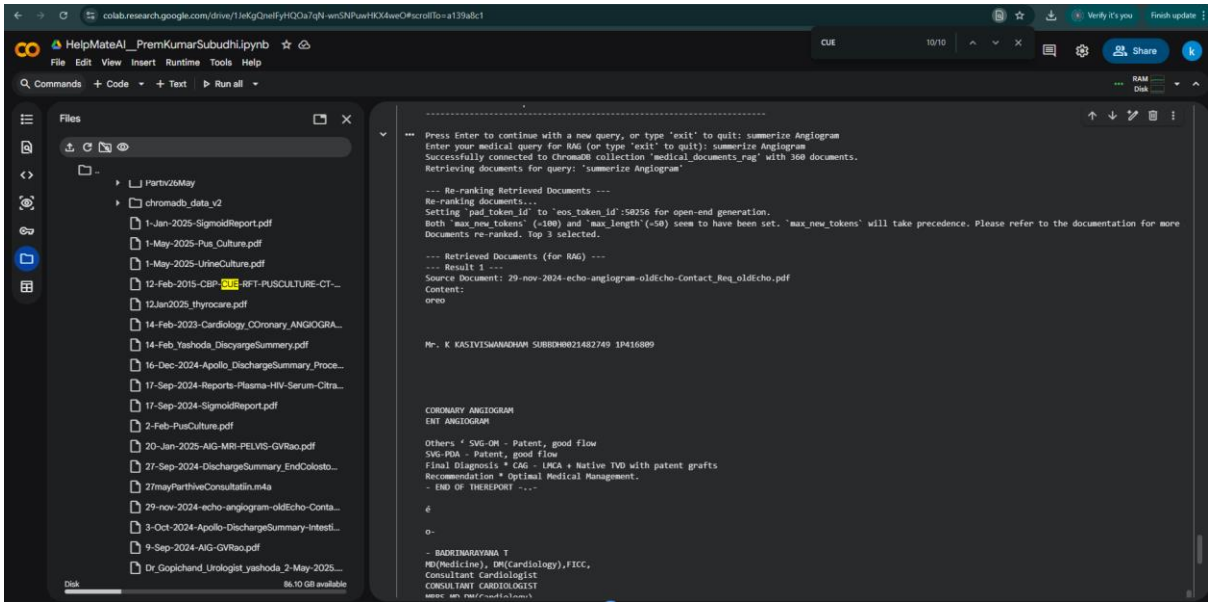

RAG pipeline successfully retrieved the correct context. The problem lies with the generation phase, specifically with distilgpt2. This model is very small and primarily designed for simple text completion, not complex information extraction, summarization, or answering specific questions from dense text. It often struggles to pinpoint precise details or synthesize them coherently, resulting in generic or incomplete answers like "The answer is:".

To get better answers, especially for extracting numerical values or detailed summaries, would need to use a significantly larger and more capable language model (e.g., a more powerful open-source model or an API-based LLM like Gemini, GPT-3.5/4, Llama 2, etc.).

GPT-2 model upgraded:

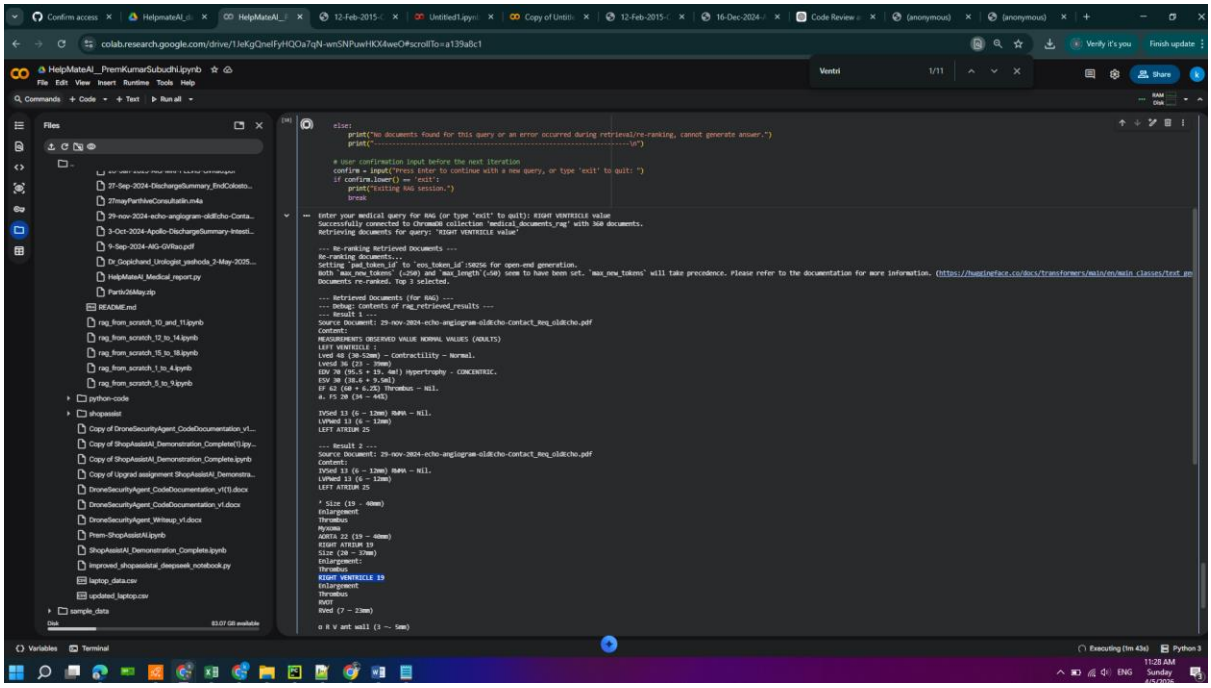

The current issue stems from the re-ranker's inability to precisely distinguish between similar medical terms, causing less relevant documents to be prioritized. To address this, I propose a multi-faceted approach to enhance both the re-ranking and the answer generation stages. This plan aims to ensure that the most relevant information is presented to the LLM for accurate extraction.

Enhance Re-ranking Strategy: Improve the re_rank_documents function. This could involve exploring more specialized CrossEncoder models trained on medical data or implementing a keyword-based boosting mechanism to prioritize documents explicitly containing key terms from the user's query (e.g., 'RIGHT VENTRICLE').

Refine LLM Extraction Prompt: Further refine the prompt within the generate_answer function. This refinement will guide the LLM to be even more precise in extracting numerical values for the exact entity specified in the query, and to explicitly state 'Information not found' if the precise value for that specific entity is not present, preventing misinterpretations from similar terms.

Test and Evaluate Improvements: After implementing the changes, thoroughly test the RAG pipeline with queries that previously failed, such as 'RIGHT VENTRICLE value'. Analyze the re-ranker's scores and the LLM's generated answers to ensure accuracy and precision.

Final Task: Summarize the improvements made to the re-ranking and answer generation, and confirm that the system now correctly extracts specific numerical values for medical entities.

Vector DB (Chrome DB) Embedding and Metadata:

https://drive.google.com/drive/folders/1UII2PIicDVwreq1qMZUrVxxRN8OvGq0L?usp=sharing

/content/drive/MyDrive/Upgrad_GenAI/HelpmateAI_dataset/chromadb_data_v2

With GPT-4O mini (Accuracy high)

Quer1:

Press Enter for a new query, or type 'exit' to quit: Gall Bladder status or vlaue

Enter your medical query (or 'exit' to quit): Gall Bladder status or vlaue

Connected to 'medical_documents_rag' (89 docs).

Retrieving for: 'Gall Bladder status or vlaue'

--- Re-ranking Retrieved Documents ---

Re-ranking documents...

Re-ranked — top 5 selected.

--- Retrieved Documents (for RAG) ---

--- Result 1 ---

Source: 12-Feb-2015-CBP-CUE-RFT-PUSCULTURE-CT-ABDOMEN.pdf

Content:

“4%

>

ASHODA

HOSPITALS

Patient Name : KASI VISWANADHAM

Sex/Age :M/81Y3M 26D

KONCHADA

YH No. : 400617651 Diag No. : 10934333

Ref. Phys. :DR. M VENKATESWARA RAO Modality :CT

Order Date/Time _—: 12-02-2025 13:11:06 IP Number :196279

Report Date/Time : 13-02-2025 12:45

Reg Type :IPD/ /840 A

DEPARTMENT OF RADIOLOGY

CT ABDOMEN WITH ORAL & RECTAL CONTRAST

TECHNIQUE:

Helical CT acquisition of abdomen was done on MDCT scanner & images were reconstructed in axial & coronal

planes with oral and rectal contrast administration.

Clinical details: Known case of CA prostate - post RT. Now presented with perianal fistula.

FINDINGS:

Stomach, duodenum, small bowel loops show normal calibre.

Cecum, ascending colon, transverse and descending colon are fecal loaded.

Appendix shows normal calibre with non opacification of the lumen. Tip is adherent to the thickened presacral

fascia. No obvious leakage of oral contrast.

There is good transit of oral contrast upto the colostomy.

Postoperative sigmoid colostomy is seen in left lumbar region.

Postoperative rectal stump shows collapsed lumen.

There is fluid collection in the right perianal region extending into right ischiorectal fossa, ischial bursa with multiple

air pockets. Inferiorly the collection is extending into the anterior perineum, along the bulb of the penis and after the

posterior root of the scrotum.

Few small air pockets are seen extending in the perirectal space along the right side of the mesorectal and

presacral fascia.

Rectal contrast shows leakage into perianal intersphincteric space, right ischiorectal fossa, ischial bursa and upto

the fistulous opening in the perineum.

Liver: Normal in size & attenuation. No IHBD. CBD is normal.

Gall bladder: Distended.

Note: This is a professional opinion only, Each investigation has its limitations. Final diagnosis needs correlation

with clinical context and other investigations. Kindly discuss, if necessary.

180K/01-25 (B)

--- Result 2 ---

Source: 14-Feb_Yashoda_DiscyargeSummery.pdf

Content:

IP. No. 196279

<%

>)

YASHODA

HOSPITALS

SERUM POTASSIUM 5.50 mmol/L

14/02/2025 SODIUM (SERUM)

SERUM SODIUM 126 mmol/L

14/02/2025 BLOOD UREA WITH BUN

BLOOD UREA 41 mg/dL

BUN 19 mg/dL

Radiology Reports:

12/02/2025

DEPARTMENT OF RADIOLOGY

CT ABDOMEN WITH ORAL & RECTAL CONTRAST

TECHNIQUE:

Helical CT acquisition of abdomen was done on MDCT scanner & images were reconstructed in axial &

coronal planes with oral and rectal contrast administration.

Clinical details: Known case of CA prostate - post RT. Now presented with perianal fistula.

FINDINGS:

Stomach, duodenum, small bowel loops show normal calibre.

Cecum, ascending colon, transverse and descending colon are fecal loaded.

Appendix shows normal calibre with non opacification of the lumen. Tip is adherent to the thickened presacral fascia. No obvious leakage of oral contrast.

There is good transit of oral contrast upto the colostomy.

Postoperative sigmoid colostomy is seen in left lumbar region.

Postoperative rectal stump shows collapsed lumen.

There is fluid collection in the right perianal region extending into right ischiorectal fossa, ischial bursa with

multiple air pockets. Inferiorly the collection is extending into the anterior perineum, along the bulb of the

penis and after the posterior root of the scrotum.

Few small air pockets are seen extending in the perirectal space along the right side of the mesorectal and

presacral fascia.

Rectal contrast shows leakage into perianal intersphincteric space, right ischiorectal fossa, ischial bursa and

upto the fistulous opening in the perineum.

Liver: Normal in size & attenuation. No IHBD. CBD is normal.

Gall bladder: Distended.

Spleen: Normal in size & attenuation.

Pancreas: Head, body & tail regions are normal.

No evidence of pancreatic calcifications or calculi.

No dilatation of pancreatic duct.

No evidence of peripancreatic fluid.

Bilateral adrenals are normal in size, shape & attenuation.

Kidneys: Normal in size, shape & attenuation. No evidence of calculus or hydronephrosis.

There is a 2.2 cm cortical cyst in midpole of left kidney.

Bilateral ureters are normal in course & calibre.

Urinary bladder is empty with Foley's catheter insitu with diffuse thickened wall and perivesical fat stranding - Possible post RT changes.

No evidence of ascites.

180K/01-25 (B)

--- Result 3 ---

Source: 12-Feb-2015-CBP-CUE-RFT-PUSCULTURE-CT-ABDOMEN.pdf

Content:

-ODA

»PITALS

: KASI VISWANADHAM

Sex/Age :M /81Y3M 26D

KONCHADA

YH No. : 400617651 Diag No. : 10934333

Ref. Phys. :DR. M VENKATESWARA RAO Modality :CT

Order Date/Time =: 12-02-2025 13:11:06 IP Number =: 196279

Report Date/Time —: 13-02-2025 12:45 ‘IPD / /840A

Reg Type

Spleen: Normal in size & attenuation.

Pancreas: Head, body & tail regions are normal.

No evidence of pancreatic calcifications or calculi.

No dilatation of pancreatic duct.

No evidence of peripancreatic fluid.

Bilateral adrenals are normal in size, shape & attenuation.

Kidneys: Normal in size, shape & attenuation. No evidence of calculus or hydronephrosis.

There ts a 2.2 cm cortical cyst in midpole of left kidney.

Bilateral ureters are normal in course & calibre.

Unmnary bladder is empty with Foley's catheter insitu with diffuse thickened wall and perivesical fat stranding -

Possible post RT changes.

No evidence of ascites.

No evidence of lymphadenopathy.

Visualized bones show osteopenia, degenerative changes in spine.

Note: This is a professional opinion only, Each investigation has its limitations. Final diagnosis needs correlation

with clinical context and other investigations. Kindly discuss, ifnecessary.

180K/01-25 (B)

--- Result 4 ---

Source: 27-Sep-2024-DischargeSummary_EndColostomy_Sigmoid_Colon.pdf

Content:

" UHID: APJ1.00214$2%4910 Health City campus, Jubilee Hills, Hyderabad - 500 096.

+91-1860 258 1066

E} apollohealthcity@apollohospitals.com

fj apollohealthcity {apollohealthhyd

For appointments or online consultation, visit www.askapollo.com

Details

ADDITIONAL DIAGNOSIS :

Chief complaint(s)

History of Past/Personal/Family

~~

Treatment Summary

Discussion

& www.apollohealthcity.com

Yup apollohealthcityhyd

Ko ollo

HOSPITALS

by seine Couunlss

RADATION PROCTITIS WITH RECTAL PERFORATION

PATIENT IS KNOWN HISTORY OF RADIATION PROCTITIS CAME WITH PERIANAL PAIN MRI WAS DONE SHOWED RECTAL PERFORATION SAME FINDINGS WERE CONFIRMED BY COLONOSCOPY

VITALS STABLE

PATINET GOT ADMITTED AND EVALUATED

ALL THE LABORATORY INVESTIGATIONS WERE DONE , MRI SHOWED A_RAECTAL PREFORATION EXTENDING INTO MESORECTUM, WITH PROCTITIS EXTENDING TILL DESCENDING COLON, SIGMOIDOSCOPY CONFIRMED THE PERFORATION WITH SLOUGH SO, AFTER PAC AND INFORMED CONSENTS PATIENT WAS PLANNED FOR LAPAROTOMY ON 18/09/2024 UNDER GENERAL ANESTHESIA. MID LINE INCISION TAKEN, BELOW PERITONEAL REFLECTION, RECTAL PERFORATION INVOLVING RETRO RECTAL/ PRE SACRAL RIGHT PARA SEMINAL VESICULAR SPACE. SPECIMEN WAS TRANSECTED AT RECTOSIGMOID/MID SIGMOID. MOBILISED TILL PERITONEAL REFLECTION, PERFORATION IDENTIFIED, DEBRIDED THROUGH WASH WAS GIVEN, SPECIMEN TRANSECTED DISTAL TO ANORECTAL

“ COMPLEX. GREATER OMENTUM SHOVED INTO PELVIC DEFECT END STOMA MATURED, DRAIN WAS PLACED AND INCISION CLOSED IN LAYERS, SPECIMEN WAS SENT TO HPE. POST.OPERATIVE PERIOD UNEVENTFUL. PATIENT WAS KEPT ON NBM UPTO POD-3 STARTED INITIAL CLER LIQUIDS FOLLOWED BY FULL LIQUIDS AND SOFT DIET. PATIENT WAS DOING WELL AND TOLERATING FEED WELL. HENCE DISCHARGING PATIENT IN STABLE CONDITION WITH FOLLOWING MEDICAL ADVICE.

Discharge Medication

Prescription Details

‘Drug Name [Strength Dosages |Frequency|Route of Relationship |Duration [Comment

|(Generic Name) Admin With Meal

DOLO 650MG TAB 650MG Oral After meal Till PAIN

15'S(PARACETAMO Tablet(s) Review

L 650MG)

ULTRACET TAB & -SMG+3| 1 Oral After meal _ |Till ;

nage SSCTRAMADOL+A [2506 JTablet(s etre onenes-s50 0 SYM ak

Ce Bertie Ident’: ‘y Number ‘CIN): [88110TN1976PL Co08035 _—

--- Result 5 ---

Source: 20-Jan-2025-AIG-MRI-PELVIS-GVRao.pdf

Content:

CSE8LODIdi766 LD.L66666N ‘ND (A JOJO]USOISED JO o}NYYsu] Uelsy JO YUN ke) sje d OH OW

Hojossqu Bf) JO ayNINsu] UkISY7 JO}!) sjeyidis I

woo'sje1d 4

jeu 7 soybiemmm @ Wwo> sjeudsoubie@oyut @ CCCP VUCY OF L6+ 8 CEO OOS - euebupla| ‘peqeiapAH 4Moqiyded ‘peoy adedspuiy| @

Name ; _ Mr KASIVISWADHAM SUBUDHI KONCHADA Accession No : 11.915082.33877

UniD : AIGG.20319146 Bill Crete 20-Jan-2025 40:51

12. Gender /Age :M/81y Reporiing Date : 20/01/2025 12:06PM

Ref. Phys. :GV Rao Modality : MR

Procedure Name : MRI PELVIS OO 7 re

ee

Left ischiorectal and ischioanal fossae are normal.

Urinary biadder is empty with Foley's insitu with edematous wall.

No free fluid in tne pelvis.

IMPRESSION:

» Large ahscess in the right ischioanal snace with communication with the anal canal and rnultiple ramifications into right gluteal region, posterior thigh, perineum and presacral space as described above.

» Communicaticn cf above collection with cecum through a partially fibrosed tract.

» Few small collections in bilateral scrotal sacs (Partially imaged) and in perineum as described.

This examination and reported findings have been reviewed and confirmed.

Approved by:

Dr. Ashirwad Pasumarthy

MD,DNB

Consultant Radiologist

KKAKKKENd Of Report * ****

--- Generating Answer with gpt-4o-mini ---

--- Final RAG Answer ---

The gall bladder is described as distended.

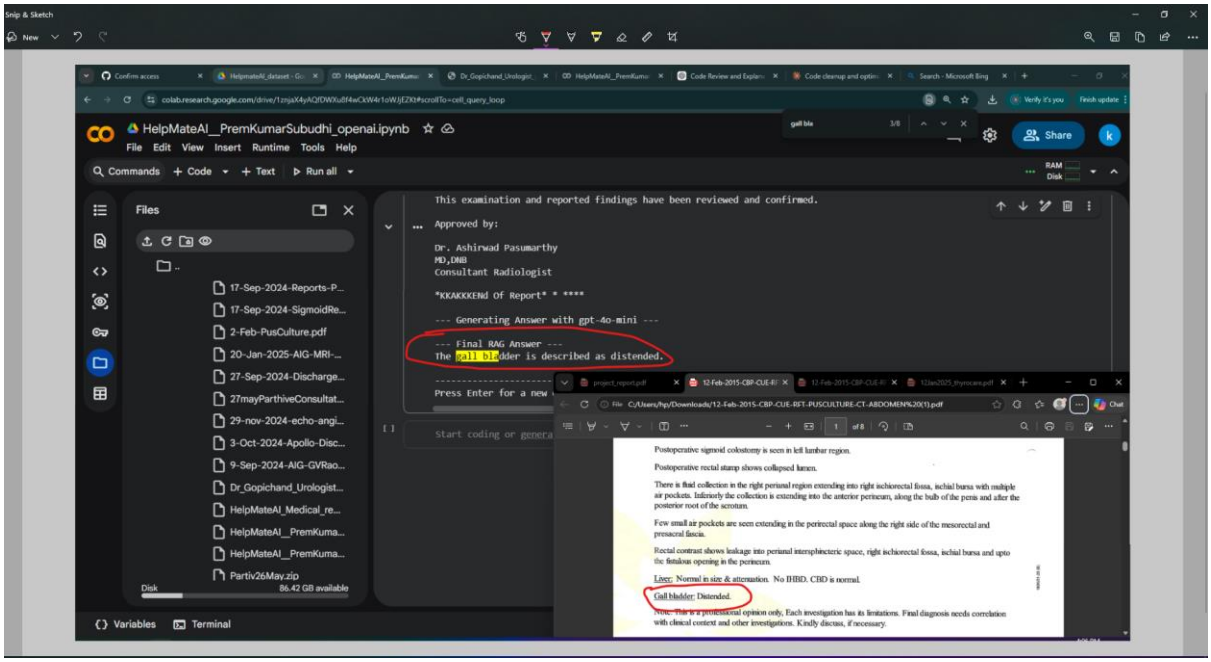

Query 2:

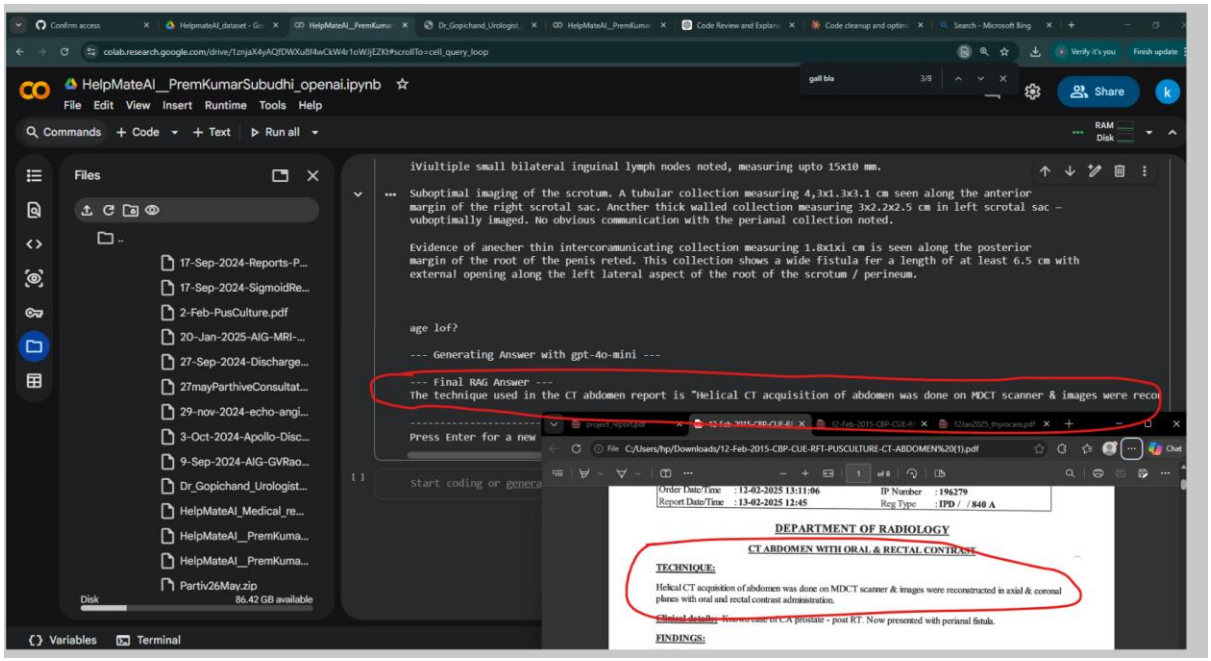

Enter your medical query (or 'exit' to quit): What is the techniq used in CT abdomen report?

Connected to 'medical_documents_rag' (89 docs).

Retrieving for: 'What is the techniq used in CT abdomen report?'

--- Re-ranking Retrieved Documents ---

Re-ranking documents...

Re-ranked — top 5 selected.

--- Retrieved Documents (for RAG) ---

--- Result 1 ---

Source: 14-Feb_Yashoda_DiscyargeSummery.pdf

Content:

IP. No. 196279

<%

>)

YASHODA

HOSPITALS

SERUM POTASSIUM 5.50 mmol/L

14/02/2025 SODIUM (SERUM)

SERUM SODIUM 126 mmol/L

14/02/2025 BLOOD UREA WITH BUN

BLOOD UREA 41 mg/dL

BUN 19 mg/dL

Radiology Reports:

12/02/2025

DEPARTMENT OF RADIOLOGY

CT ABDOMEN WITH ORAL & RECTAL CONTRAST

TECHNIQUE:

Helical CT acquisition of abdomen was done on MDCT scanner & images were reconstructed in axial &

coronal planes with oral and rectal contrast administration.

Clinical details: Known case of CA prostate - post RT. Now presented with perianal fistula.

FINDINGS:

Stomach, duodenum, small bowel loops show normal calibre.

Cecum, ascending colon, transverse and descending colon are fecal loaded.

Appendix shows normal calibre with non opacification of the lumen. Tip is adherent to the thickened presacral fascia. No obvious leakage of oral contrast.

There is good transit of oral contrast upto the colostomy.

Postoperative sigmoid colostomy is seen in left lumbar region.

Postoperative rectal stump shows collapsed lumen.

There is fluid collection in the right perianal region extending into right ischiorectal fossa, ischial bursa with multiple air pockets. Inferiorly the collection is extending into the anterior perineum, along the bulb of the penis and after the posterior root of the scrotum.

Few small air pockets are seen extending in the perirectal space along the right side of the mesorectal and presacral fascia.

Rectal contrast shows leakage into perianal intersphincteric space, right ischiorectal fossa, ischial bursa and upto the fistulous opening in the perineum.

Liver: Normal in size & attenuation. No IHBD. CBD is normal.

Gall bladder: Distended.

Spleen: Normal in size & attenuation.

Pancreas: Head, body & tail regions are normal.

No evidence of pancreatic calcifications or calculi.

No dilatation of pancreatic duct.

No evidence of peripancreatic fluid.

Bilateral adrenals are normal in size, shape & attenuation.

Kidneys: Normal in size, shape & attenuation. No evidence of calculus or hydronephrosis.
There is a 2.2 cm cortical cyst in midpole of left kidney.

Bilateral ureters are normal in course & calibre.

Urinary bladder is empty with Foley's catheter insitu with diffuse thickened wall and perivesical fat stranding - Possible post RT changes.

No evidence of ascites.

180K/01-25 (B)

--- Result 2 ---
Source: 12-Feb-2015-CBP-CUE-RFT-PUSCULTURE-CT-ABDOMEN.pdf
Content:
“4%
>
ASHODA
HOSPITALS

Patient Name : KASI VISWANADHAM

Sex/Age :M/81Y3M 26D

KONCHADA

YH No. : 400617651 Diag No. : 10934333

Ref. Phys. :DR. M VENKATESWARA RAO Modality :CT

Order Date/Time _—: 12-02-2025 13:11:06 IP Number :196279

Report Date/Time : 13-02-2025 12:45

Reg Type :IPD/ /840 A

DEPARTMENT OF RADIOLOGY

CT ABDOMEN WITH ORAL & RECTAL CONTRAST

TECHNIQUE:

Helical CT acquisition of abdomen was done on MDCT scanner & images were reconstructed in axial & coronal

planes with oral and rectal contrast administration.

Clinical details: Known case of CA prostate - post RT. Now presented with perianal fistula.

FINDINGS:

Stomach, duodenum, small bowel loops show normal calibre.

Cecum, ascending colon, transverse and descending colon are fecal loaded.

Appendix shows normal calibre with non opacification of the lumen. Tip is adherent to the thickened presacral

fascia. No obvious leakage of oral contrast.

There is good transit of oral contrast upto the colostomy.

Postoperative sigmoid colostomy is seen in left lumbar region.

Postoperative rectal stump shows collapsed lumen.

There is fluid collection in the right perianal region extending into right ischiorectal fossa, ischial bursa with multiple

air pockets. Inferiorly the collection is extending into the anterior perineum, along the bulb of the penis and after the

posterior root of the scrotum.

Few small air pockets are seen extending in the perirectal space along the right side of the mesorectal and

presacral fascia.

Rectal contrast shows leakage into perianal intersphincteric space, right ischiorectal fossa, ischial bursa and upto

the fistulous opening in the perineum.

Liver: Normal in size & attenuation. No IHBD. CBD is normal.

Gall bladder: Distended.

Note: This is a professional opinion only, Each investigation has its limitations. Final diagnosis needs correlation

with clinical context and other investigations. Kindly discuss, if necessary.

180K/01-25 (B)

--- Result 3 ---

Source: 17-Sep-2024-Reports-Plasma-HIV-Serum-CitratedPlasma-WholeBloodEDTA.pdf

Content:

MC-2493

Name ‘Mr. KASIVISWANADHAM SUBUDHI Age: 80Yr 10Mth 30Days Gender : Male

UHID : KENCHYBPAb2749 1 1P472841 W/BNo/RefNo : 1st FloorSpecial

SIN \LRN : 125350499 \ 11053877 Ward/120 B

Specimen : Citrated Plasma

Ref Doctor : Dr.DR.KISHORE ALAPATI AND DR. VARUGHESE MATHAI

IRA A

Collected on : 17-SEP-2024 12:19:16 AM Received on : 17-SEP-2024 01:22:38 AM Reported on : 17-SEP-2024 02:37:28 AM

SURGICAL PROFILE Ill (Without Chest CT Screening)

J°ST.NAME RESULT BIOLOGICAL REFERENCE INTERVALS UNITS

4=IVATED PARTIAL THROMBOPLASTIN TIME : (Automation-electromechanical clot detection method)

| 31.1 28 - 40 sec

Control ; 30.0

Equipment Name STA COMPACT MAX-STAGO

COMMENTS: APTT is frequently used:

1.As a screening test to detect certain coagulation factor deficiency.

2.Detection of coagulation inhibitor.

3.In screening of lupus anticoagulant.

4.For heparin monitoring.

NOTE: APTT is elevated in patients on heparin and it is observed the sensitivity of heparin to APTT has wide variability based

on the type of heparin and the reagents used for testing, hence lab has not established heparin sensitivity to APTT.

602/17/tr/tr/tr-tr

Report Status:Final

KINDLY CORRELATE RESULTS WITH CLINICAL FINDINGS.

* END OF REPORT *

CHECKED BY : 1264947

zg :

4 .

wt a 6@

First Report Printed On : 17-SEP-2024 10:23:27 AM a

Dr.Noora Mohammed Ahmed

Printed On: 17-SEP-2024 10:25:06 AM .

Junior Consultant

--- Result 4 ---

Source: 12-Feb-2015-CBP-CUE-RFT-PUSCULTURE-CT-ABDOMEN.pdf

Content:

-ODA

»PITALS

: KASI VISWANADHAM

Sex/Age :M /81Y3M 26D

KONCHADA

YH No. : 400617651 Diag No. : 10934333

Ref. Phys. :DR. M VENKATESWARA RAO Modality :CT

Order Date/Time =: 12-02-2025 13:11:06 IP Number =: 196279

Report Date/Time —: 13-02-2025 12:45 ‘IPD / /840A

Reg Type

Spleen: Normal in size & attenuation.

Pancreas: Head, body & tail regions are normal.

No evidence of pancreatic calcifications or calculi.

No dilatation of pancreatic duct.

No evidence of peripancreatic fluid.

Bilateral adrenals are normal in size, shape & attenuation.

Kidneys: Normal in size, shape & attenuation. No evidence of calculus or hydronephrosis.

There ts a 2.2 cm cortical cyst in midpole of left kidney.

Bilateral ureters are normal in course & calibre.

Unmnary bladder is empty with Foley's catheter insitu with diffuse thickened wall and perivesical fat stranding -

Possible post RT changes.

No evidence of ascites.

No evidence of lymphadenopathy.

Visualized bones show osteopenia, degenerative changes in spine.

Note: This is a professional opinion only, Each investigation has its limitations. Final diagnosis needs correlation

with clinical context and other investigations. Kindly discuss, ifnecessary.

180K/01-25 (B)

--- Result 5 ---

Source: 20-Jan-2025-AIG-MRI-PELVIS-GVRao.pdf

Content:

Name : Mr KASIVISWADHAM SUBUDHI KONCHADA Accession No : 11.915082.33877

UHID : AIGG.20919146 Bill Date : 20-Jan-2025 10:51

Gender/Age :M/81 y Reporting Date : 20/01/2025 12:06PM

Ref. Phys. :GV Rao Modality :MR

Procedure Name: MRI PELVIS

mene

DEPARTMENT OF RADIO-DIAGNOSIS AND IMAGING

MRI PELVIS

TECHNIQUE:

T1, T2, T2 Fat Sat coronals.

T1, T2, T2 Fat Sat Axials.

T2 Sagittal.

FINDINGS:

Large well-defined fluid collection showing multiple air pockets is noted in the pelvis along right lateral wall,

measures 7.1x4.9x5.6 cm (TRXAPXCC). Collection shows:

* Continuity with anal canal through a defect extending from 9 o'clock to 12 o'clock position with an

approximate length of defect measuring 3.5 cm and width measuring 2 cm.

¥ €xtends into right intersphincteric space and shows a large defect in the right external sphincter from 7

o'clock tu 10 o'clock po-ition and measures 3.8 cm in length.

« Further extends superiorly into right mesorectal space.

* — Laterally, there is a defect in the right levator ani muscle and extends upto right ischial tuberosity and

iliac bones.

» Few blind ending tracks noted in the right gluteal muscles with one of the ramification measuring 5 cm in

iangth in the right posterior thieh miuscles and extends upto the neck of the femur,

Anteviorly, the collection is extending into right obturator internus muscle.

Superiorly, evidence of a thin tract is seen tracking along the presacral space upto the level of S1

vertebra, where it shows few sinus tracts leading to the ileal loops and base of the cecum. Evidence of

corrmunication is noted with the cecal lumen.

-Significant soft tissue thickening and fat stranding noted in the pelvis, predominantly on right side.

~oony changes with few defects ere ncted in the right ischial tuberosity.

iViultiple small bilateral inguinal lymph nodes noted, measuring upto 15x10 mm.

Suboptimal imaging of the scrotum. A tubular collection measuring 4,3x1.3x3.1 cm seen along the anterior

margin of the right scrotal sac. Ancther thick walled collection measuring 3x2.2x2.5 cm in left scrotal sac —

vuboptimally imaged. No obvious communication with the perianal collection noted.

Evidence of anecher thin intercoramunicating collection measuring 1.8x1xi cm is seen along the posterior

margin of the root of the penis reted. This collection shows a wide fistula fer a length of at least 6.5 cm with

externa! opening along the left lateral aspect of the root of the scrotum / perineum.

age lof?

--- Generating Answer with gpt-4o-mini ---

--- Final RAG Answer ---

The technique used in the CT abdomen report is "Helical CT acquisition of abdomen was done on MDCT scanner & images were reconstructed in axial & coronal planes with oral and rectal contrast administration."

Query 3:

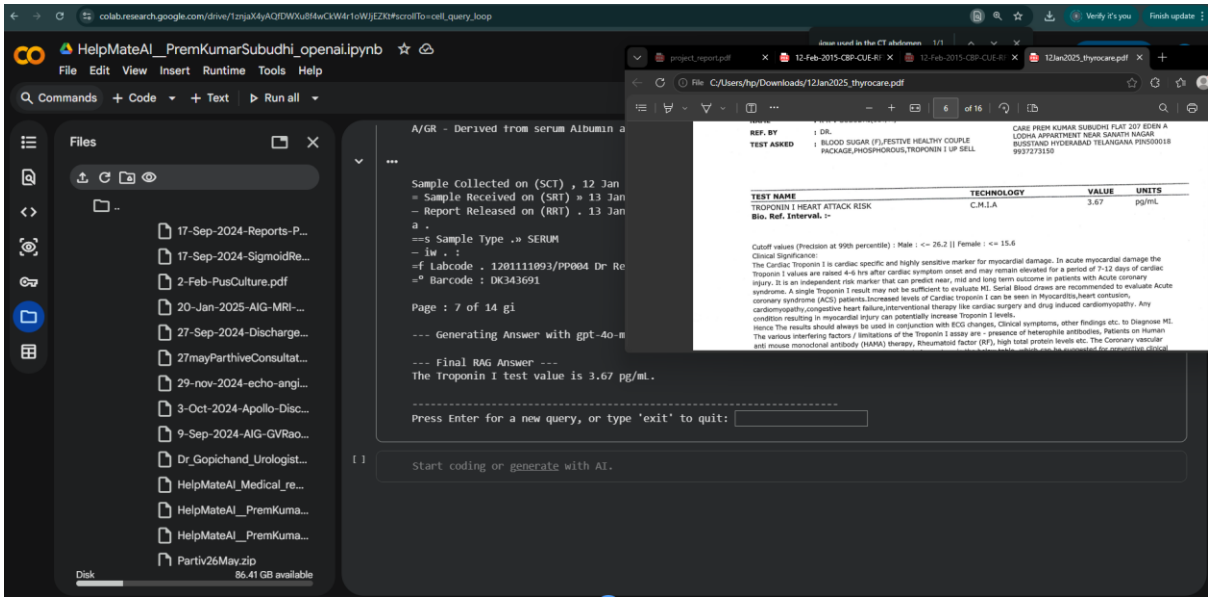

Press Enter for a new query, or type 'exit' to quit: TROPONIN test value

Enter your medical query (or 'exit' to quit): TROPONIN test value

Connected to 'medical_documents_rag' (89 docs).

Retrieving for: 'TROPONIN test value'

--- Re-ranking Retrieved Documents ---

Re-ranking documents...

Re-ranked — top 5 selected.

--- Retrieved Documents (for RAG) ---

--- Result 1 ---

Source: 12Jan2025_thyrocare.pdf

Content:

NA A

160586590

PROCESSED AT :

Thyrocare

D-37/1,TTC MIDC,Turbhe,

Navi Mumbai-400 703

4 Thyrocare’

Tests you can trust

MC-2407

Corporate Office : Thyrocare Technologies Limited, @ D-37/1, TTC MIDC, Turbhe, Navi Mumbai - 400 703

© 022 - 3090 0000 / 6712 3400 (© 9870666333 W wellness@thyrocare.com @® www.thyrocare.com

NAME : K K V SUBUDHI(81Y/M) HOME COLLECTION :

REF. BY : DR. CARE PREM KUMAR SUBUDHI FLAT 207 EDEN A

TEST ASKED: BLOOD SUGAR (F),FESTIVE HEALTHY COUP! E USCTAND HYDERABAD TELANGANA PINSOOOLS

PACKAGE,PHOSPHOROUS, TROPONIN I UP SELL

9937273150

ens mre een ett TC CT

TEST NAME TECHNOLOGY VALUE UNITS

TROPONIN I HEART ATTACK RISK C.M.I.A 3.67

pg/mL

Bio. Ref. Interval. :-

Cutoff values (Precision at 99th percentile) : Male : <= 26.2 || Female : <= 15.6

Clinical Significance:

The Cardiac Troponin I is cardiac specific and highly sensitive marker for myocardial damage. In acute myocardial damage the

Troponin I values are raised 4-6 hrs after cardiac symptom onset and may remain elevated for a period of 7-12 days of cardiac

injury. It is an independent risk marker that can predict near, mid and long term outcome in patients with Acute coronary

syndrome. A single Troponin I result may not be sufficient to evaluate MI. Serial Blood draws are recommended to evaluate Acute

coronary syndrome (ACS) patients.Increased levels of Cardiac troponin I can be seen in Myocarditis,heart contusion,

cardiomyopathy congestive heart failure,interventional therapy like cardiac surgery and drug induced cardiomyopathy. Any

candition resulting in myocardial injury can potentially increase Troponin I levels.

Hence The results should always be used in conjunction with ECG changes, Clinical symptoms, other findings etc. to Diagnose MI.

The various interfering factors / limitations of the Troponin I assay are - presence of heterophile antibodies, Patients on Human

anti mouse monoclonal antibody (HAMA) therapy, Rheumatoid factor (RF), high total protein levels etc. The Coronary vascular

disease risk stratification in Asymptomatic patients is as given in the below table, which can be suggested for preventive clinical

management in conjunction with other clinical findings, investigations and clinical symptoms.

The following cut-off points may be used to aid in stratifying the risk of cardiovascular disease in asymptomatic individuals.

enone vemewtascornaemnsensuinanae eerste A

[|

HIGH SENSITIVE TROPONIN-I LEVEL

INTERPRETATION ;

Low risk of future heart attack |

Moderate risk of future heart attack —

__. | Elevated risk of future heart attack “|

Specifications: Precision at the 99th Percentiles

Females = 15.6 pg/mL -5.3% CV || Males = 34.2pg/mL - 3.5% CV

Kit validation reference :

1. Risk-Stratification of the Apparently Healthy Population for Future Cardiac Events With ARCHITECT High Sensitive

Troponin-I(https://dam.abbott.com/de-de/documents/pdf/ADD- 00064393-hsTnI-Risk-Stratification-Sell-Sheet.pdf)

2. ARCHITECT STAT High Sensitive Troponin-I [package insert]. Lake Bluff, IL: Abbott Laboratories; 2018. G97079R0O1.

1c AA AL TET A

Please correlate with clinical conditions.

Method:- FULLY AUTOMATED CHEMI LUMINESCENT MICROPARTICLE IMMUNOASSAY

ee ER A A

sunset tte ane ITN TNE TITER

eataansarsssee

Sample Collected on (SCT) .12 Jan 2025 07:09

Sample Received on (SRT) .13 Jan 2025 04:38

Report Released on (RRT) , 13 Jan 2025 10:21

--- Result 2 ---

Source: 12Jan2025_thyrocare.pdf

Content:

7

4 Thyrocare’

Tests you can trust

PROCESSED AT:

Thyrocare ACCREDITED

D lars 3 7/ 1 ,TTC MI DC,Tu rb h e, COLLEGE of AMERICAN PATHOLOGISTS.

Navi Mumbai-400 703

Corporate Office : Thyrocare Technologies Limited, Y D-37/1, TTC MIDC, Turbhe, Navi Mumbai - 400 703

© 022 - 3090 0000 / 6712 3400 © 9870666333 wm wellness@thyrocare.com @) www.thyrocare.com

NAME : K K V SUBUDHI(81Y/M) HOME COLLECTION :

REF. BY = DR. CARE PREM KUMAR SUBUDHI FLAT 207 EDEN A

TEST ASKED : FESTIVE HEALTHY COUPLE PACKAGE,TROPONIN | UP LODHA APPARTMENT NEAR SANATH NAGAR

SELL,FBS,PHOS BUSSTAND HYDERABAD TELANGANA PIN500018

Summary Report

TESTNAME sc OBSERVED VALUE _ UNITS ____Bio. Ref. Interval. _

THYROID

TOTAL TRIIODOTHYRONINE (T3) 30 ng/dL 58-159

TOXIC ELEMENTS

BERYLLIUM 0.03 ug/L 0.10 - 0.80

URINOGRAM

URINARY BILIRUBIN Present 1+(1-3 mg/dl) mg/dL Absent

URINARY PROTEIN Trace (15-30 mg/dl) mg/dL Absent

VITAMIN

VITAMIN B-12 > 2000 pg/mL 197-771

Disclaimer: The above listed is the summary of the parameters with values outside the BRI. For detailed report values,

parameter correlation and clinical interpretation, kindly refer to the same in subsequent pages.

HA

D160586594

--- Result 3 ---

Source: 12Jan2025_thyrocare.pdf

Content:

PROCESSED AT :

Thyrocare

D-37/1,TTC MIDC,Turbhe,

Navi Mumbai-400 703

>

Thyrocare’

Tests you can trust

MC-2407

Corporate Office : Thyrocare Technologies Limited, D-37/1, TTC MIDC, Turbhe, Navi Mumbai - 400 703

© 022 - 3090 0000 / 6712 3400 (© 9870666333 4 wellness@thyrocare.com @ www.thyrocare.com

NAME : K K V SUBUDHI(81Y/M) HOME COLLECTION :

REF. BY : DR. CARE PREM KUMAR SUBUDHI FLAT 207 EDEN A

LODHA APPARTMENT NEAR SANATH NAGAR

TEST ASKED , BLOOD SUGAR (F),FESTIVE HEALTHY COUPLE

PACKAGE, PHOSPHOROUS, TROPONIN I UP SELL ee TELANGANA PIN500018

co re

TEST NAME	TECHNOLOGY	VALUE	UNITS
EST. GLOMERULAR FILTRATION RATE (eGFR)	CALCULATED	69	mL/min/1.73

Bio. Ref. Interval. :-

> = 90 : Normal

60-89 _ : Mild Decrease

45-59 : Mild to Moderate Decrease

30-44 : Moderate to Severe Decrease

15-29 : Severe Decrease

Clinical Significance

The normal serum creatinine reference interval does not necessarily reflect a normal GFR for a patient. Because mild and moderate

kidney injury is poorly inferred from serum creatinine alone. Thus, it is recommended for clinical laboratories to routinely estimate

glomerular filtration rate (eGFR), a “gold standard” measurement for assessment of renal function, and report the value when

serum creatinine is measured for patients 18 and older, when appropriate and feasible. It cannot be measured easily in clinical

practice, instead, GFR is estimated from equations using serum creatinine, age, race and sex. This provides easy to interpret

information for the doctor and patient on the degree of renal impairment since it approximately equates to the percentage of

kidney function remaining. Application of CKD-EPI equation together with the other diagnostic tools in renal medicine will further

improve the detection and management of patients with CKD.

Reference

Levey AS, Stevens LA, Schmid CH, Zhang YL, Castro AF, 3rd, Feldman HI, et al. A new equation to estimate glomerular filtration

rate. Ann Intern Med. 2009;150(9):604-12.

snc vonnavnensucunsienermentiuennrsiaretnasatne inert

sccxininanansnaninnmensinaesenienstananpameartinnsanmcsieaensnianerateiinsatamannennttnen nit NT ee

Please correlate with clinical conditions.

Method:- CKD-EPI Creatinine Equation

ovnariceunaniasnsereesnmintteme estan serannnarensr

12 Jan 2025 07:09

mm 62 Sample Collected on (SCT) :

—

=—s Sample Received on (SRT) . 13 Jan 2025 04:38

== 2 :

—t Report Released on (RRT) , 13 Jan 2025 10:21

--- Result 4 ---

Source: 12Jan2025_thyrocare.pdf

Content:

A

D160586584

PROCESSED AT :

Thyrocare ACCREDITED” ip

D-37/1,TTC MIDC,Turbhe, eS eee {g Thyroca re

Navi Mumbai-400 703

Tests you can trust

Corporate Office : Thyrocare Technologies Limited, @ D-37/1, TTC MIDC, Turbhe, Navi Mumbai - 400 703

© 022 - 3090 0000 / 6712 3400 © 9870666333 8% wellness@thyrocare.com @ www.thyrocare.com

NAME : KK V SUBUDHI(81Y/M) HOME COLLECTION :

REF. BY = DR. CARE PREM KUMAR SUBUDHI FLAT 207 EDEN A LODHA

. APPARTMENT NEAR SANATH NAGAR BUSSTAND

TEST ASKED : BLOOD SUGAR (F),FESTIVE HEALTHY COUPLE HYDERABAD TELANGANA PIN500018 9937273150

PACKAGE,PHOSPHOROUS, TROPONIN I UP SELL

TEST NAME TECHNOLOGY VALUE UNITS Bio. Ref. Interval.

TOTAL TRIIODOTHYRONINE (T3) C.M.I.A 30 ng/dL 58-159

TOTAL THYROXINE (T4) C.M.L.A 6.26 ug/dL 4.87-11.72

TSH - ULTRASENSITIVE C.M.LA 4.018 uIU/mL 0.35-4.94

The Biological Reference Ranges is specific to the age group. Kindly correlate clinically.

Method :

T3,T4,USTSH - Fully Automated Chemi Luminescent Microparticle Immunoassay

Disclaimer :Results should always be interpreted using the reference range provided by the laboratory that

performed the test. Different laboratories do tests using different technologies, methods and using different reagents

which may cause difference. In reference ranges and hence it is recommended to interpret result with assay specific

reference ranges provided in the reports. To diagnose and monitor therapy doses, it is recommended to get tested

every time at the same Laboratory.

cesT ANARCHIST TTC BEIM

nen rennet

Sample Collected on (SCT) : 12 Jan 2025 07:09

Sample Received on (SRT) » 13 Jan 2025 04:38 af’

Report Released on (RRT) : 13 Jan 2025 10:21 ny he c

--- Result 5 ---

Source: 12Jan2025_thyrocare.pdf

Content:

PROCESSED AT : CAP

Thyrocare

D-37/1,TTC MIDC,Turbhe, ACCREDITED easesntiee

ACCREDITED’ & Thyrocare’

Navi Mumbai-400 703 : MC-2407 Tests you can trust

Corporate Office : Thyrocare Technologies Limited, D-37/1, TTC MIDC, Turbhe, Navi Mumbai - 400 703

© 022 - 3090 0000 / 6712 3400 © 9870666333 W% wellness@thyrocare.com @) wwwa.thyrocare.com

NAME : K K V SUBUDHI(81Y/M) HOME COLLECTION :

CARE PREM KUMAR SUBUDHI FLAT 207 EDEN A LODHA

APPARTMENT NEAR SANATH NAGAR BUSSTAND

TEST ASKED : BLOOD SUGAR (F),FESTIVE HEALTHY COUPLE HYDERABAD TELANGANA PIN500018 9937273150

REF. BY : DR.

PACKAGE,PHOSPHOROUS, TROPONIN I UP SELL

ne enemies Ce

TEST NAME TECHNOLOGY VALUE UNITS Bio. Ref.

ALKALINE PHOSPHATASE PHOTOMETRY 73.2 U/L 45-129

BILIRUBIN - TOTAL PHOTOMETRY 0.77 mg/dL 0.3-1,2

BILIRUBIN -DIRECT PHOTOMETRY 0.24 ma/dL < 0.3

BILIRUBIN (INDIRECT) CALCULATED 0.53 mg/dL 0-0.9

GAMMA GLUTAMYL TRANSFERASE (GGT) PHOTOMETRY 22.8 U/L < 55

ASPARTATE AMINOTRANSFERASE (SGOT) PHOTOMETRY 17.3 U/L <35

ALANINE TRANSAMINASE (SGPT) PHOTOMETRY 21.7 U/L < 45

SGOT / SGPT RATIO CALCULATED 0.8 Ratio <2

PROTEIN - TOTAL PHOTOMETRY 6.49 gm/dL 5.7-8.2

ALBUMIN - SERUM PHOTOMETRY 2.71 gm/dL 3.2-4.8

SERUM GLOBULIN CALCULATED 3.78 gm/dL 2.5-3.4

SERUM ALB/GLOBULIN RATIO CALCULATED 0.72 Ratio 0.9-2

eam wssensrnaianinitt nsenmenmsnr nat
snsmeuasnsettousauuienvernrananuacusuanansnsnvminnss
nitumsrahiNinlisQiiieunennrtintnisnhtinintnrn.sut inns aenseniunmunnunenuassiinenit

Please correlate with clinical conditions.

Method :

ALKP - Modified IFCC method

BILT - Vanadate Oxidation

BILD - Vanadate Oxidation

BILI - Derived from serum Total and Direct Bilirubin values

GGT - Modified IFCC method

SGOT - IFCC* Without Pyridoxal Phosphate Activation

SGPT - IFCC* Without Pyridoxal Phosphate Activation

OT/PT - Derived from SGOT and SGPT values.

PROT - Biuret Method

SALB - Albumin Bcgimethod (Colorimetric Assay Endpoint)

SEGB - DERIVED FROM SERUM ALBUMIN AND PROTEIN VALUES

A/GR - Derived from serum Albumin and Protein values

Sample Collected on (SCT) , 12 Jan 2025 07:09 7

= Sample Received on (SRT) » 13 Jan 2025 04:38 ;

— Report Released on (RRT) . 13 Jan 2025 10:21 M

a .

==s Sample Type .» SERUM

— iw . :

=f Labcode . 1201111093/PP004 Dr Renuka MD(Path) Dr Arshiya MD(Path)

=° Barcode : DK343691

--- Generating Answer with gpt-4o-mini ---

--- Final RAG Answer ---

The Troponin I test value is 3.67 pg/mL.